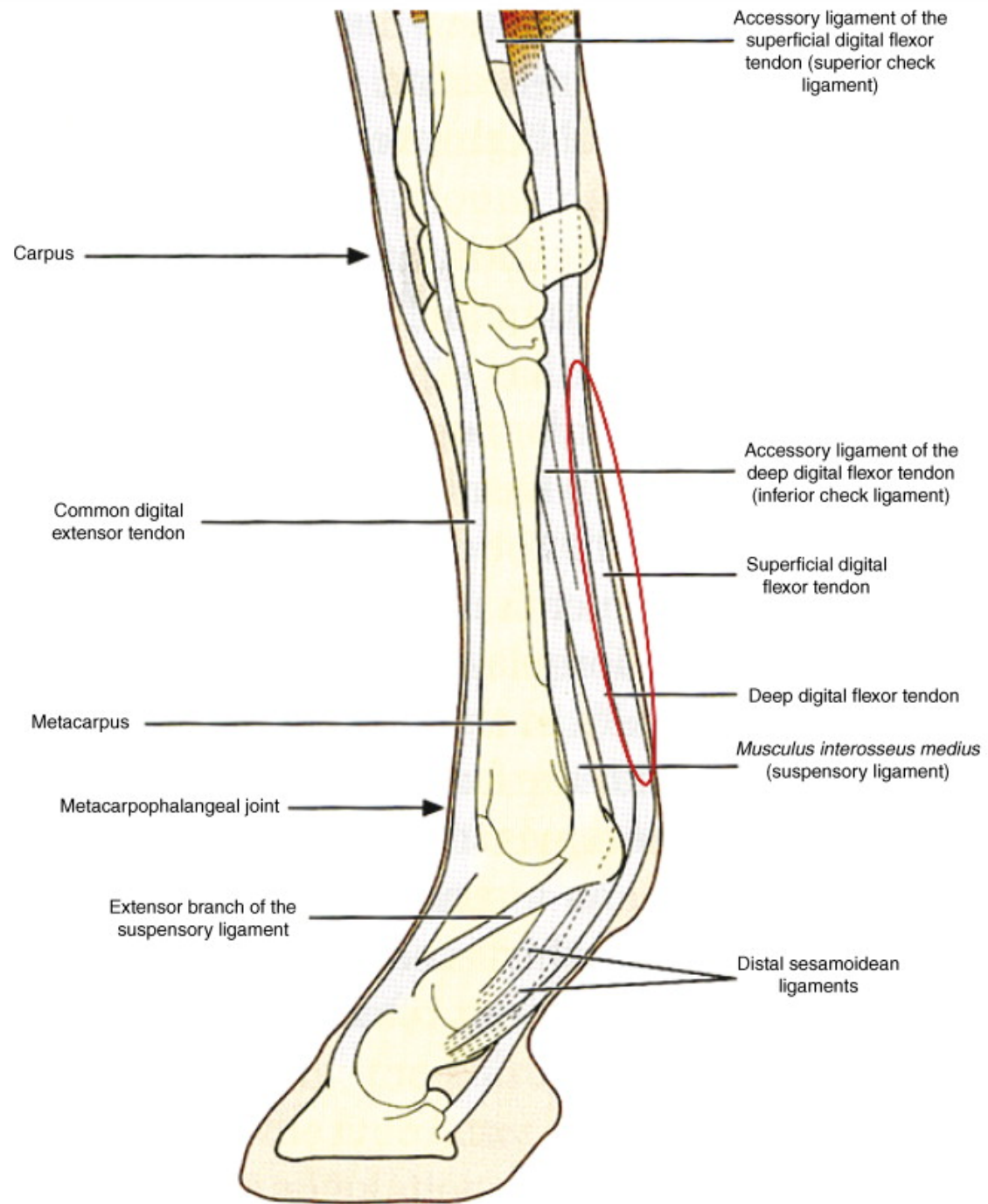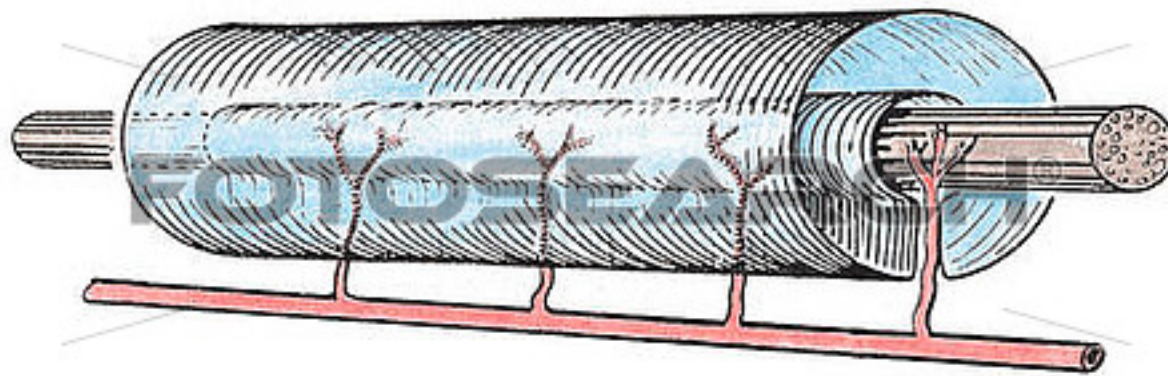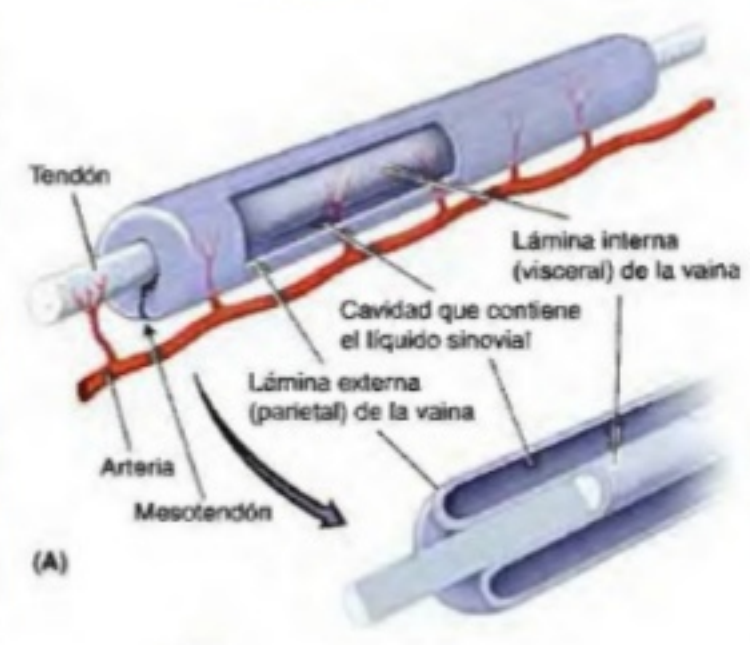
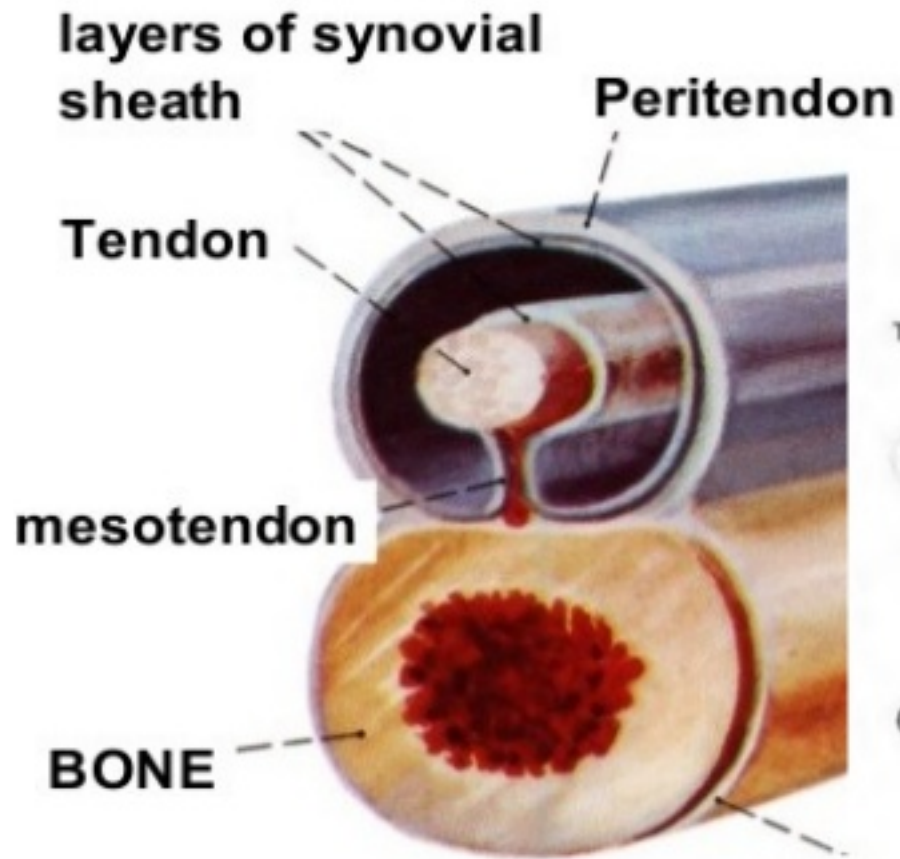
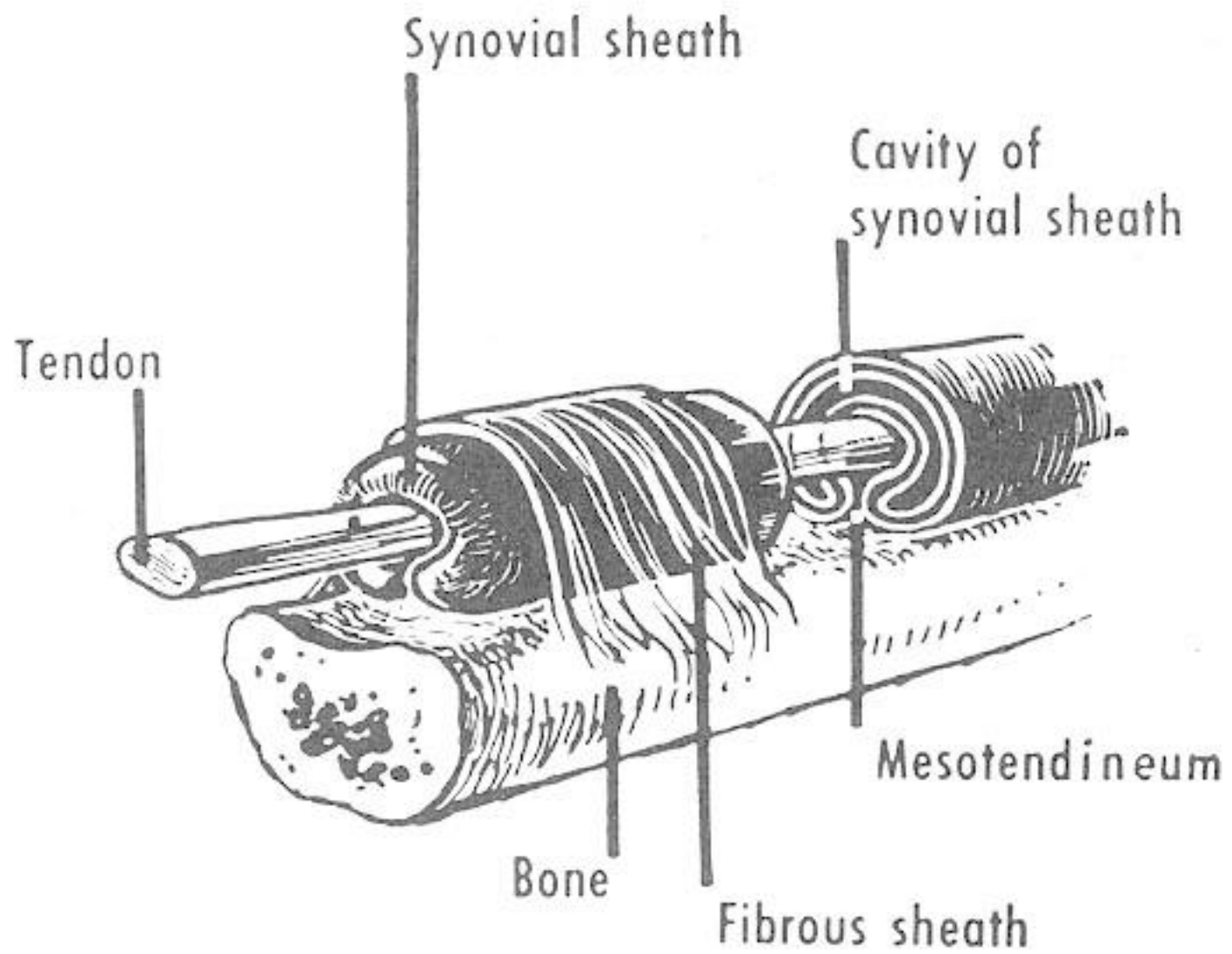


ga232019 www.fotosearch.com

# TENDON SHEATH (VAGINA TENDINIS)



Periosteum



# Short Muscles of Little

## Flexor digiti minimi

**Origin:** Flexor retinaculum

**Insertion:** Base of proximal phalanx of little finger

**NS:** Deep branch of ulnar nerve

**Action:** Flexes little finger

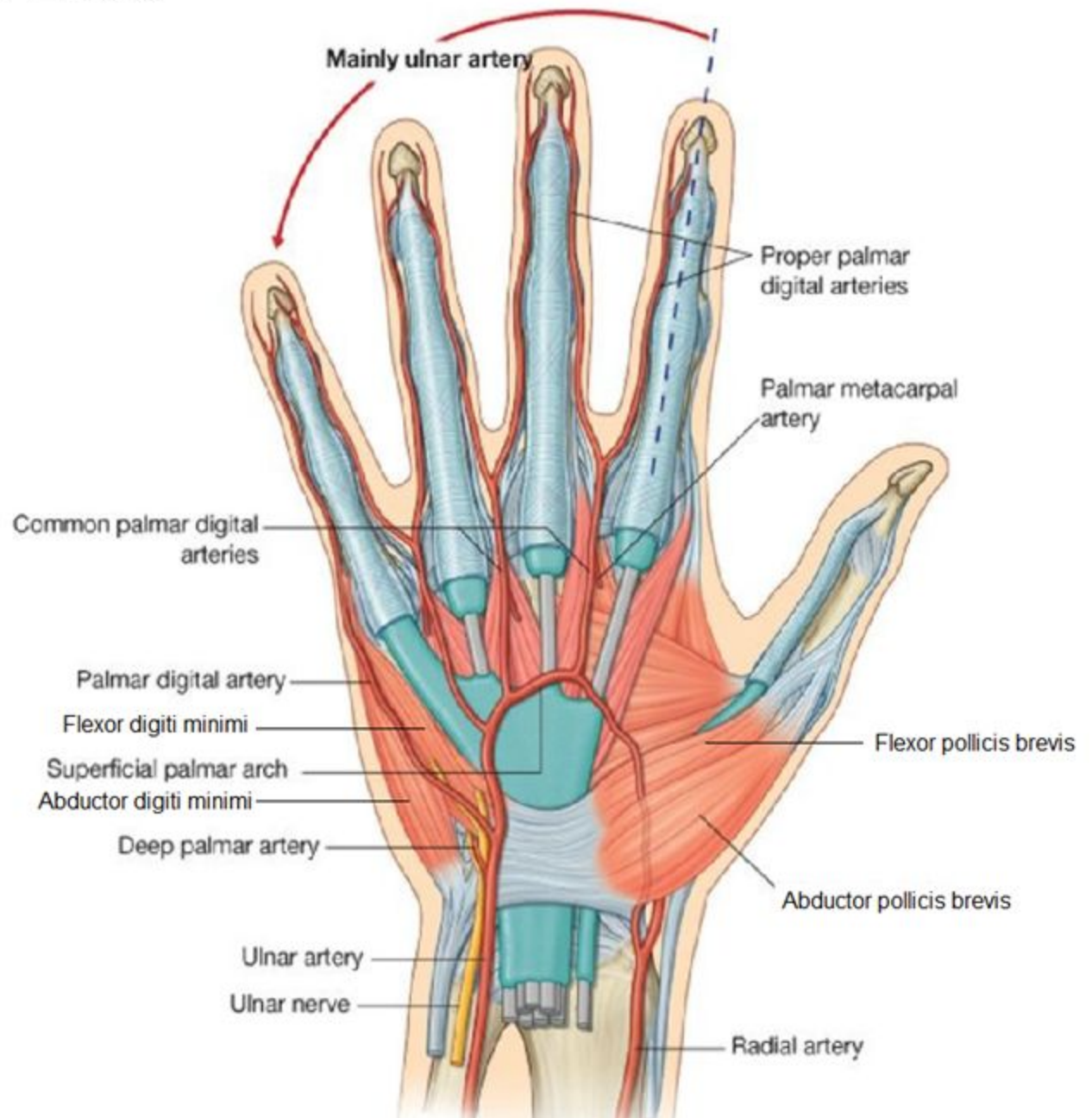
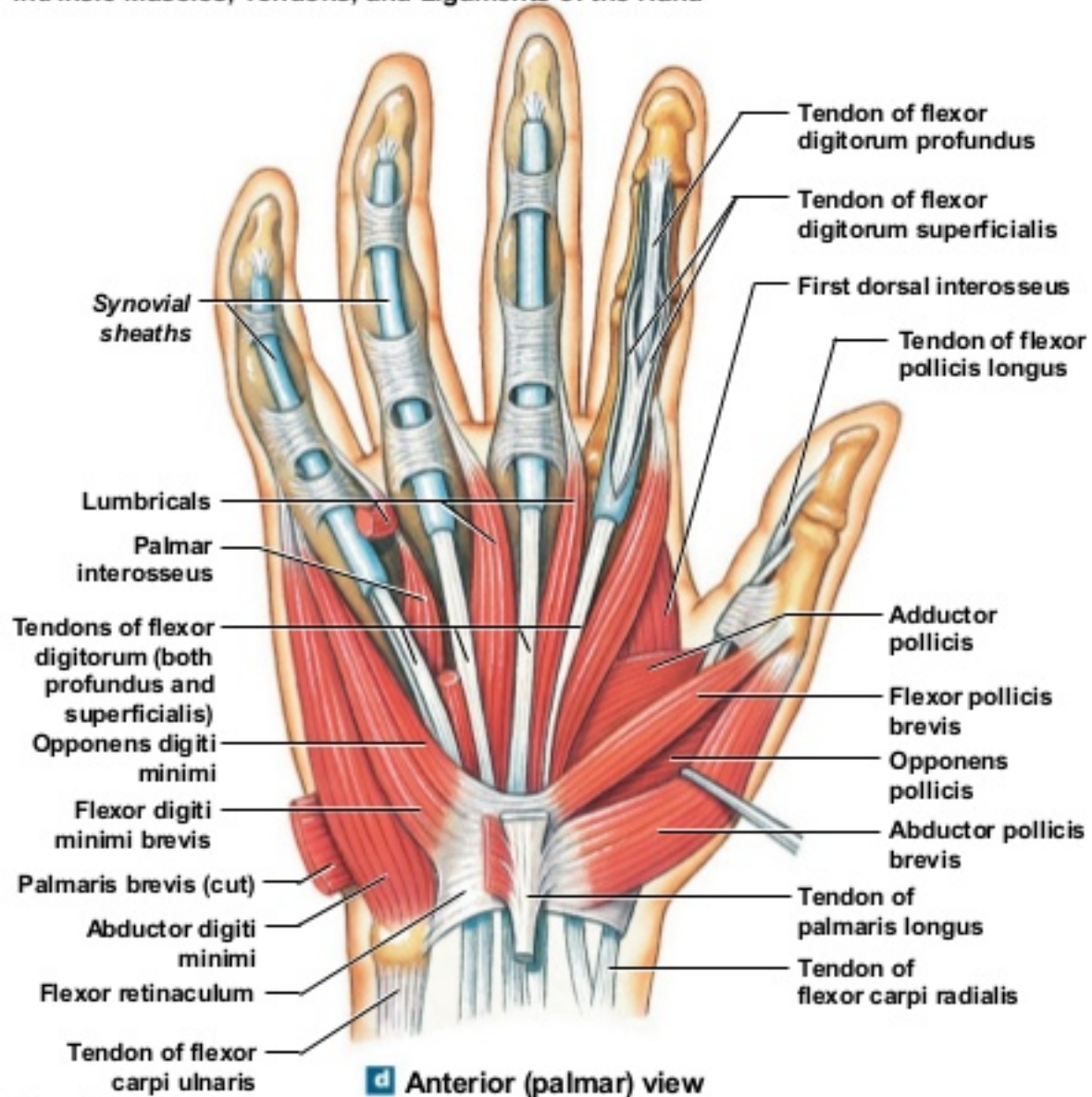
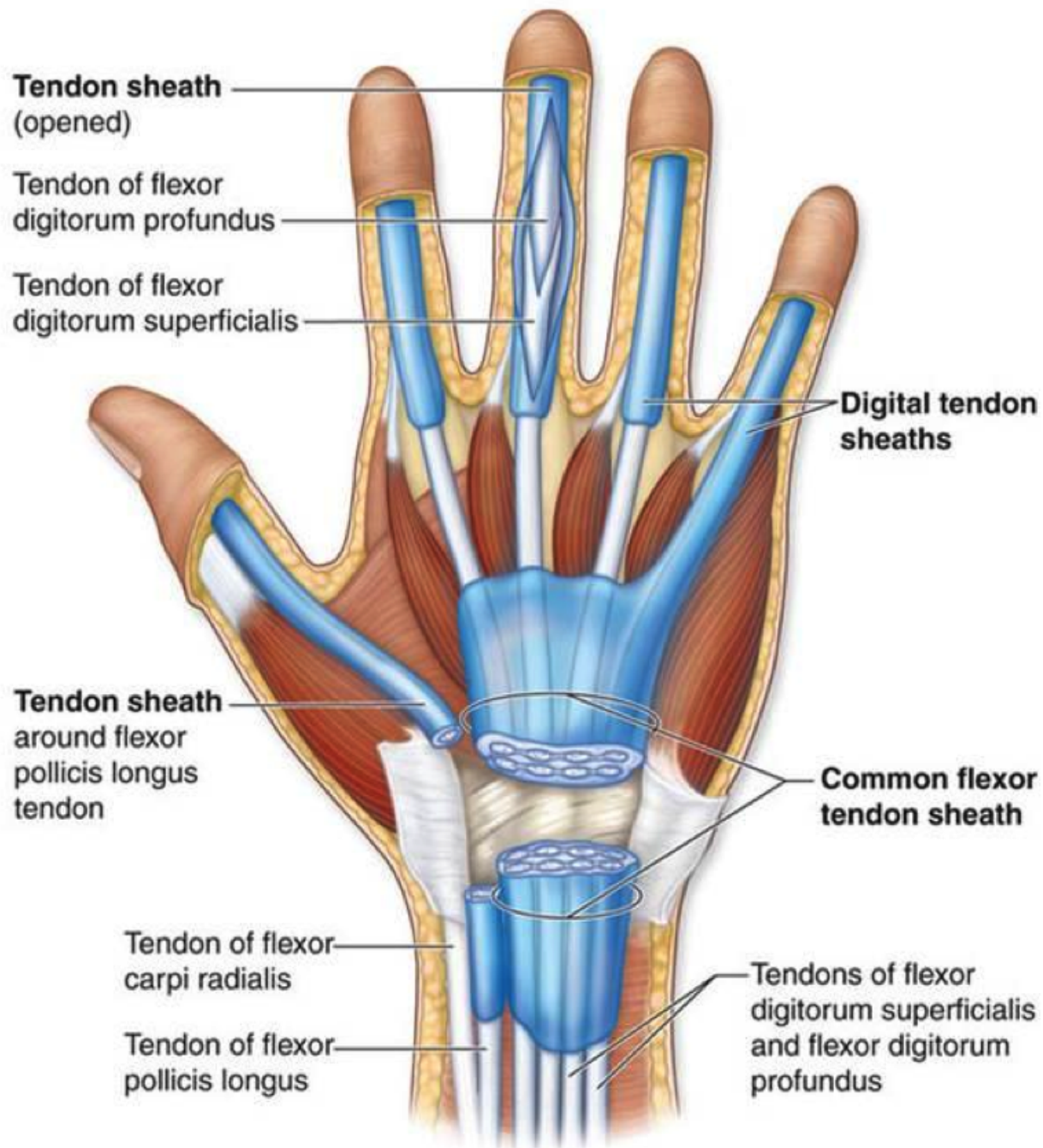


Figure 11.11d Intrinsic Muscles, Tendons, and Ligaments of the Hand

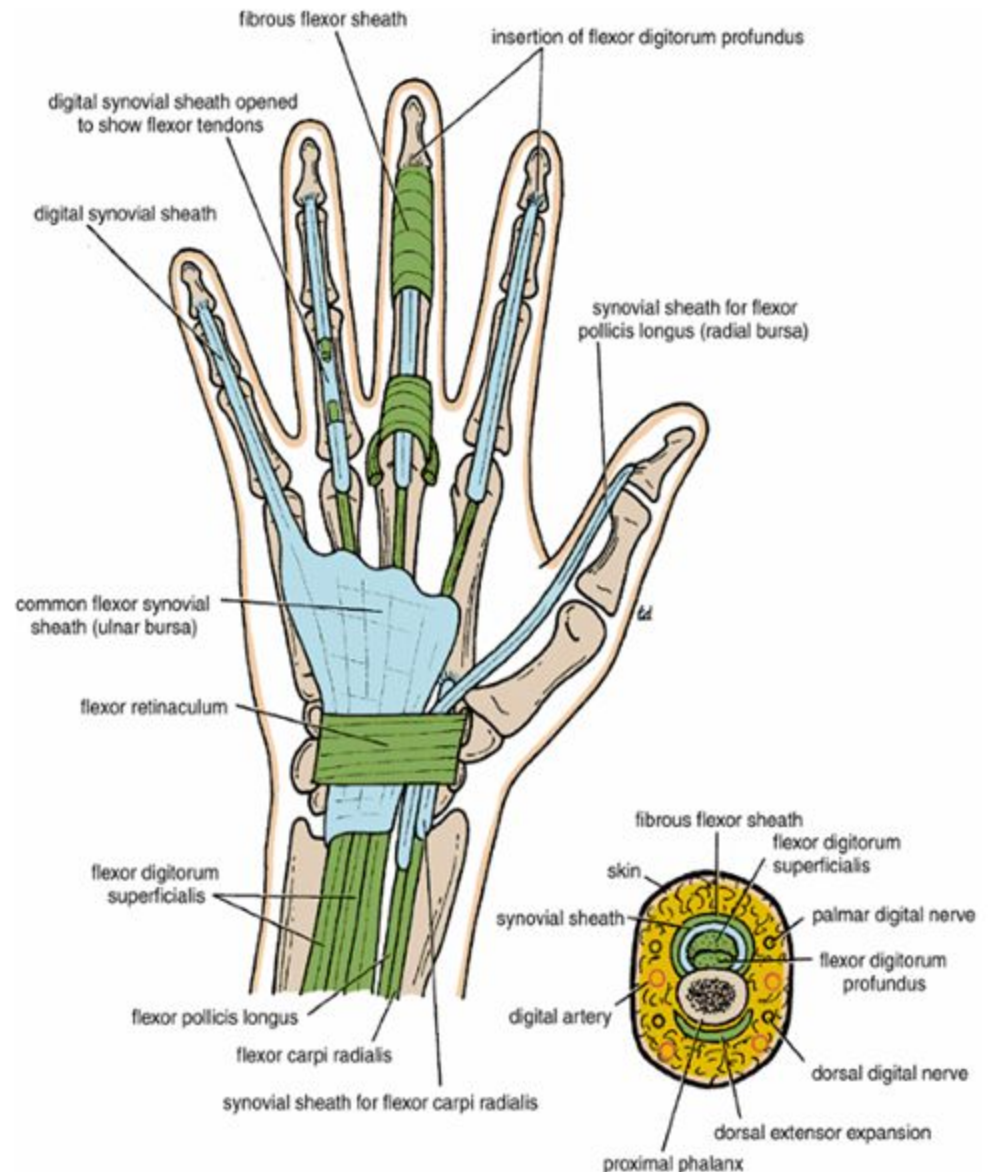




**(b) Tendon sheaths of wrist and hand, anterior view**

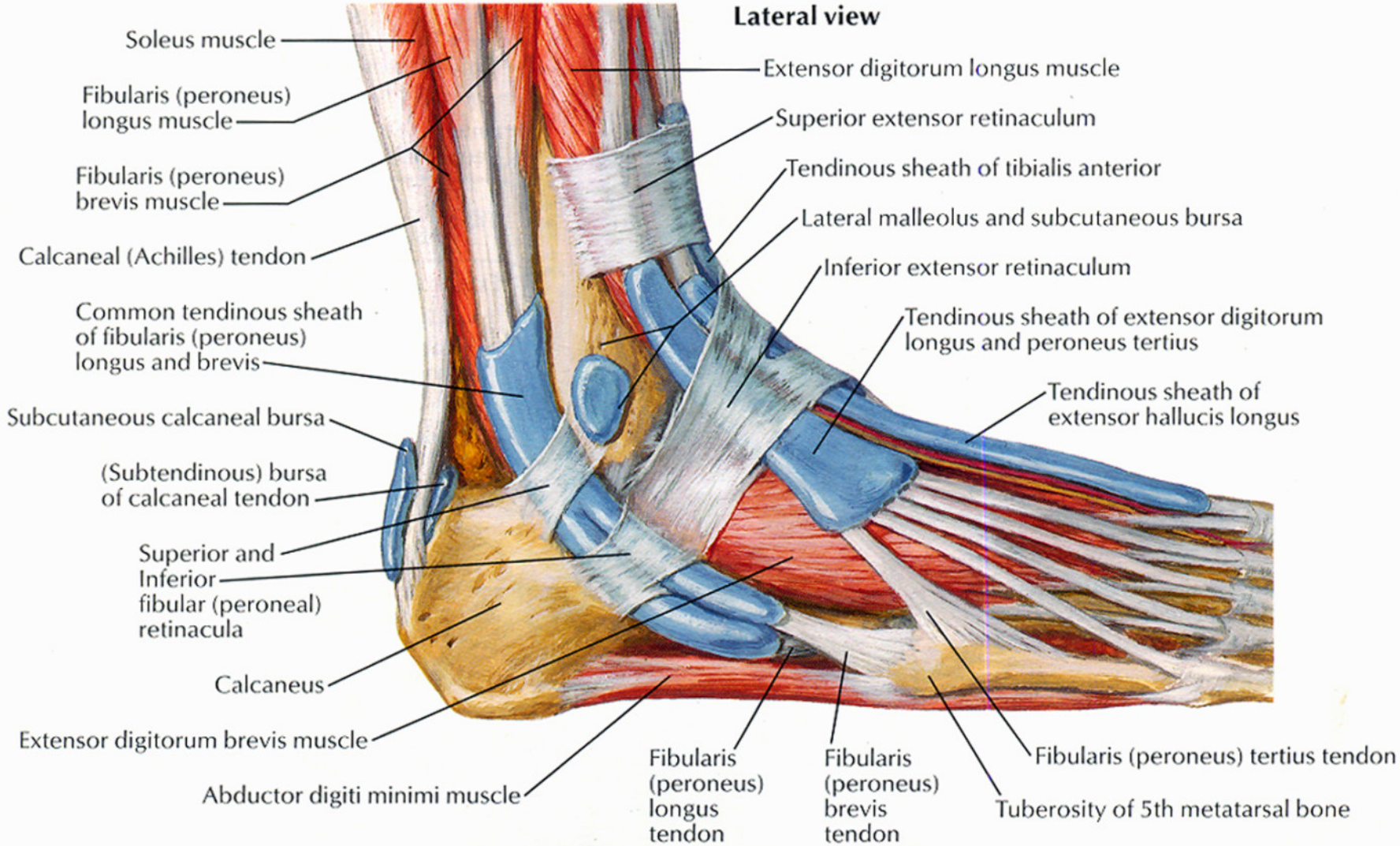
# Synovial Flexor Sheaths

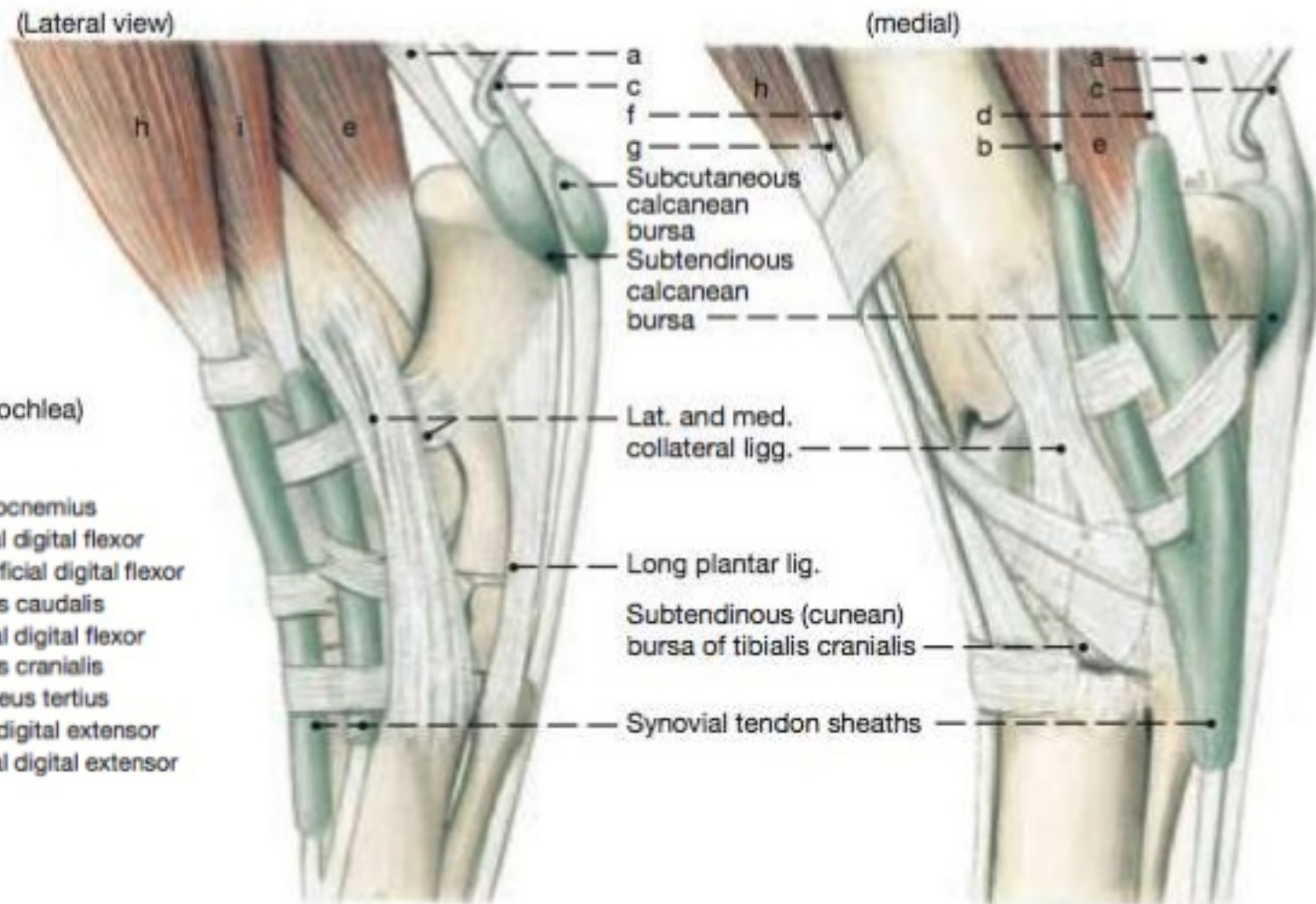
- the tendons of the flexor digitorum superficialis and profundus muscles invaginate a common synovial sheath from the lateral side
- The medial part of this common sheath extends distally without interruption on the tendons of the little finger
- The lateral part of the sheath stops abruptly on the middle of the palm, and the distal ends of the long flexor tendons of the index, the middle, and the ring fingers acquire digital synovial sheaths as they enter the fingers
- The flexor pollicis longus tendon has its own synovial sheath that passes into the thumb
- These sheaths allow the long tendons to move smoothly, with a minimum of friction, beneath the flexor retinaculum and the fibrous flexor sheaths.
- The synovial sheath of the flexor pollicis longus (sometimes referred to as the radial bursa) communicates with the common synovial sheath of the superficialis and profundus tendons (sometimes referred to as the ulnar bursa) at the level of the wrist in about 50% of subjects
- The vincula longa and brevia are small vascular folds of synovial membrane that connect the tendons to the anterior surface of the phalanges, and convey blood vessels to the tendons.

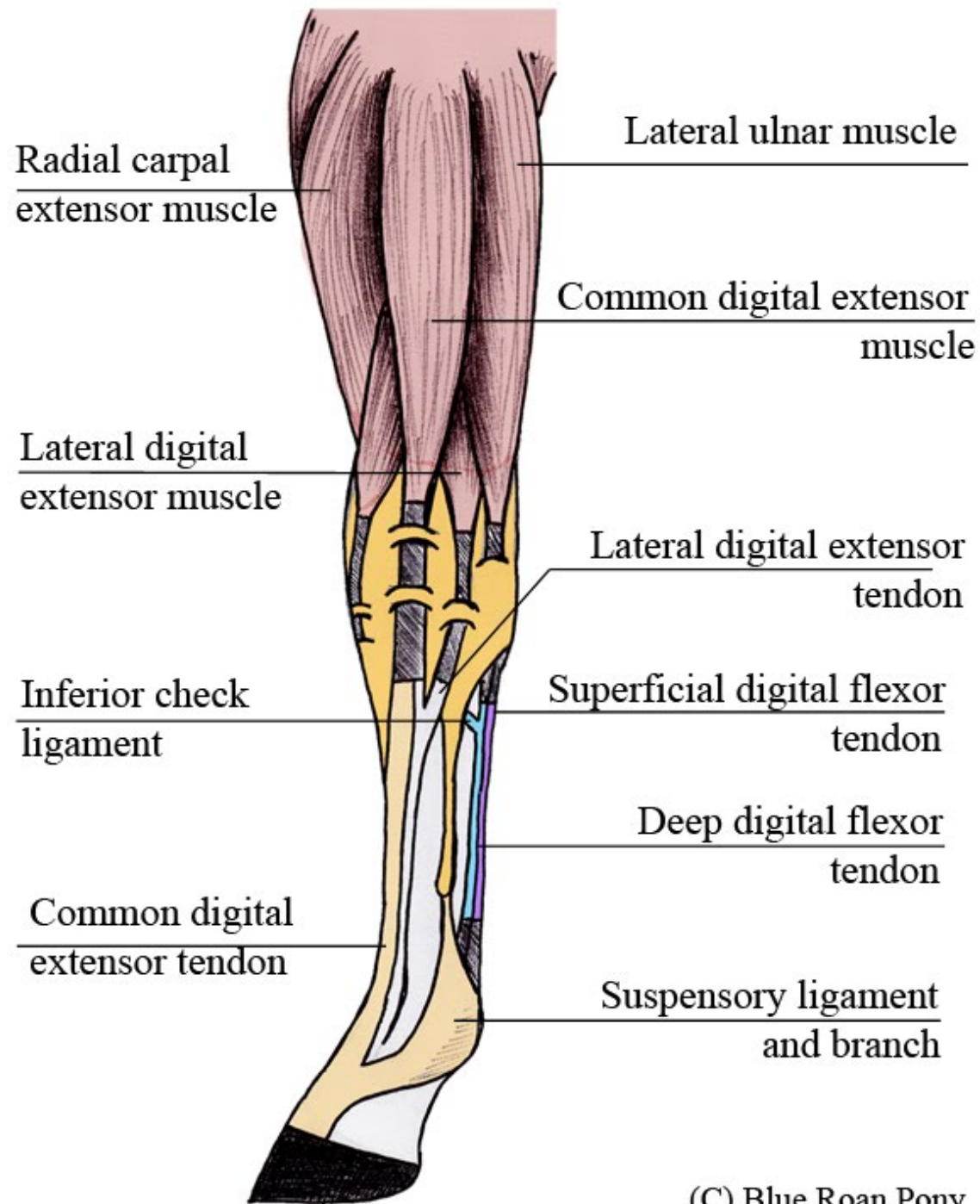




**Lateral view**

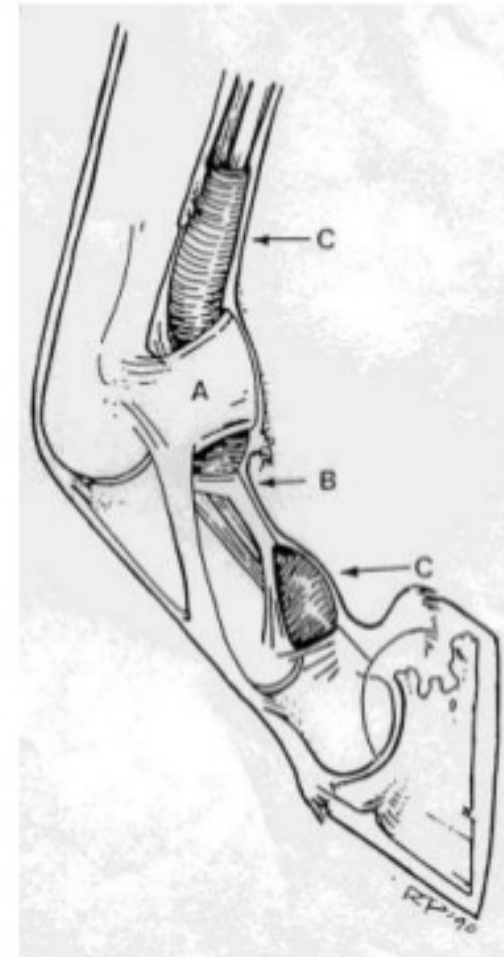






# Digital Synovial Sheath Anatomy

- **Proximal extent** ~ distal third of metacarpus
- **Distal extent**= T ligament (intersection of navicular bursa, palmar coffin joint and digital sheath)



# Digital Synovial Sheath Anatomy

- Synovial structure- similar to joints and bursae
- Outer fibrous layer and inner synovial layer.

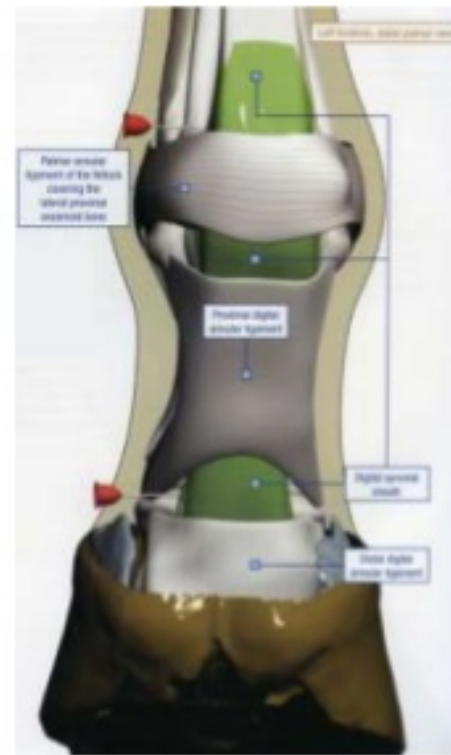
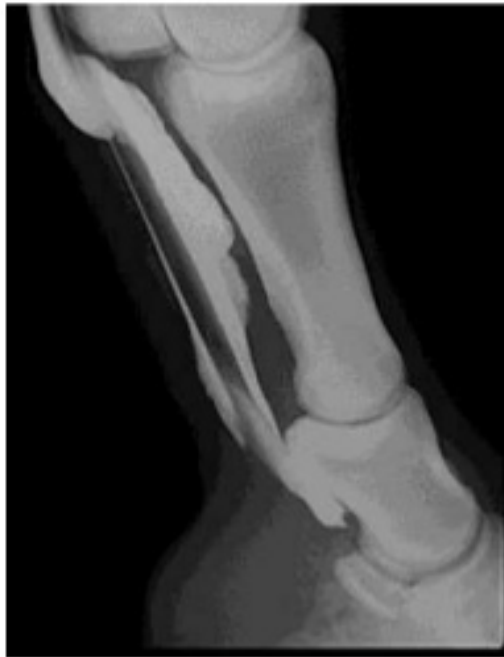

Image from Moyer et al Equine Joint Injection and Regional Anesthesia

# Tendon sheaths

- j Flex carpi radialis (resected)
- k Ext carpi radialis
- m CDE (humeral head)
- n CDE (radial head)
- o DDF
- p Lat dig flexor
- q **Ulnaris lateralis**
- r **Flexor carpi ulnaris** (resected)
- s Ext carpi obliquus

All tendons passing over carpus have sheath, except:

- Short tendon of Ulnaris lateralis
- Flexor carpi ulnaris

